



Vestibular evoked myogenic potentials in vestibular neuronitis

Tereza GABELIĆ¹, Ivan ADAMEC¹, Magdalena KRBOT¹, Velimir IŠGUM¹, Sanja HAJNŠEK^{1,2} and Mario HABEK^{1,2}

¹Department of Neurology, University Hospital Center Zagreb, Referral Center for Demyelinating Diseases of the Central Nervous System, Zagreb, Croatia; ²Department of Neurology, School of Medicine, University of Zagreb, Zagreb, Croatia

Key words: Vestibular neuronitis; cervical and ocular vestibular evoked myogenic potentials.

A 60-year-old patient presented with vertigo. He had spontaneous horizontal nystagmus with a torsional component toward the left ear and abnormal head impulse test to the right. Brain MRI was negative. Cervical and ocular vestibular evoked myogenic potentials (cVEMP and oVEMP) showed decreased amplitudes, meaning decreased responses from the

saccular (cVEMP) and utricular (oVEMP) stimulation (Fig. 1). These observations were attributed to involvement of both the superior and the inferior branch of the vestibular nerve.

The VEMP is a short-latency myogenic response evoked by brief pulses of air-conducted sound and recorded using surface muscle electrodes (1). The cVEMP assesses the descending vestibular pathway as an ipsilateral sacculocollic reflex and the oVEMP evaluates the ascending vestibular pathway as a crossed vestibulo-ocular reflex (2). As the superior

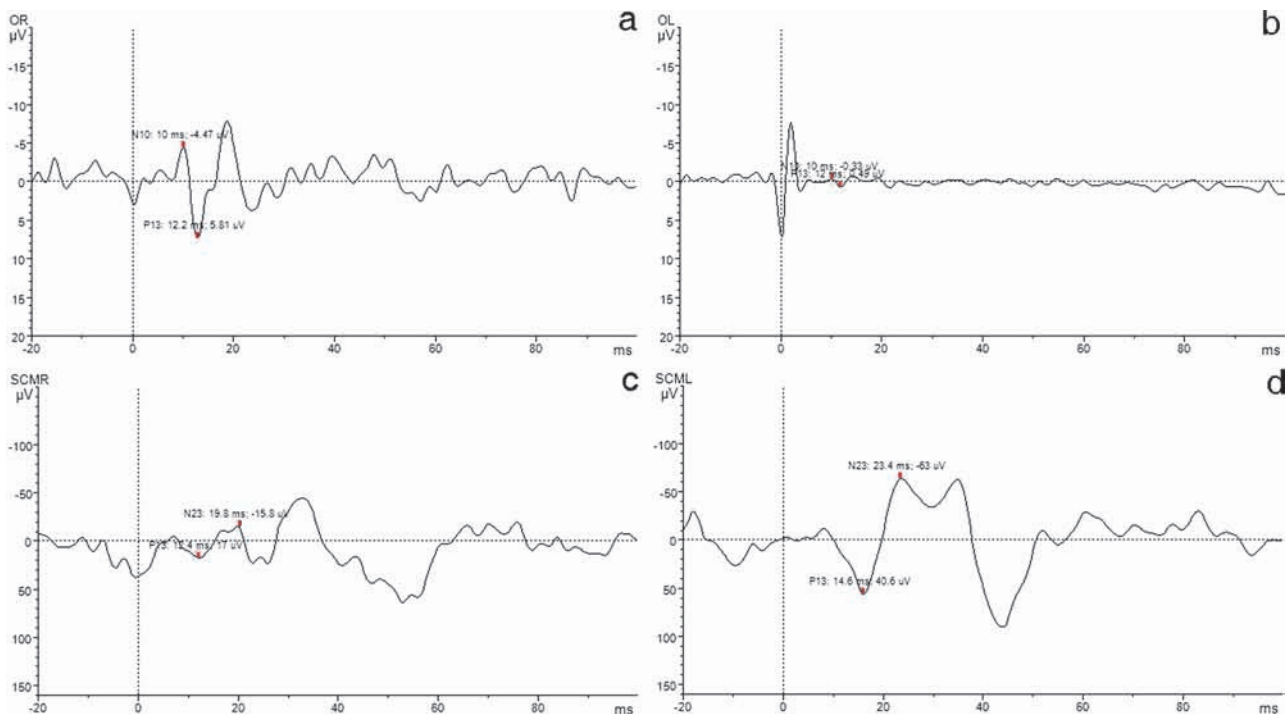


FIG. 1. — Both ears were stimulated with acoustic clicks of 30 dB intensity, 1 ms duration, 1 Hz frequency. There were 50 stimulations for each ear:

- a) and d): left ear stimulation – normal findings of OR and SCML.
- b) and c): right ear stimulation – decreased amplitude of OL and SCMR consistent with vestibular neuronitis affecting superior and inferior branch of the right vestibular nerve.

vestibular nerve supplies the superior and lateral semicircular canals as well as the utricle, and the inferior vestibular nerve supplies the posterior canal and the saccule, it has been suggested that oVEMP actually assesses superior and cVEMP inferior branch of the vestibular nerve. This means that the patient had pan-vestibular neuronitis, which is uncommon knowing that the inferior branch is affected in only 20-30% of patients (1). In conclusion, the routine use of the VEMPs provides a more complete initial assessment of the dizzy patient.

Authors' contributions

Study concept and design: Gabelić, Adamec, Habek. Acquisition of data: Krbot, Adamec, Išgum. Analysis and interpretation of data: Gabelić, Adamec, Krbot, Išgum, Hajnšek, Habek. Drafting of the manuscript: Gabelić. Critical revision of the manuscript for important intellectual content: Gabelić, Adamec, Krbot, Išgum, Hajnšek, Habek. Administrative, technical, and material support: Gabelić, Adamec, Išgum, Krbot.

Conflict of interest statement

There is no conflict of interest.

REFERENCES

1. Rosengren SM, Welgampola MS, Colebatch JG. Vestibular evoked myogenic potentials: past, present and future. *Clin Neurophysiol.* 2010;121:636-51.
2. Chou CH, Wang SJ, Young YH. Feasibility of the simultaneous ocular and cervical vestibular-evoked myogenic potentials in unilateral vestibular hypofunction. *Clin Neurophysiol.* 2009;120:1699-705.

Mario Habek, M.D., Ph.D.,
University Department of Neurology,
Zagreb School of Medicine and
University Hospital Center,
Kišpatićeva 12,
HR-10000 Zagreb (Croatia).
E-mail: mhabek@mef.hr